

Sonographic Finding of Medial Ankle Subcutaneous Edema and Its Association with Posterior Tibial Tenosynovitis

Kyle L. Dammeyer, Chad L. Klochko, Steven B. Soliman*

Division of Musculoskeletal Radiology, Department of Radiology, Henry Ford Hospital, Detroit, MI, USA

Abstract

Background: To evaluate if the sonographic finding of medial ankle subcutaneous (subQ) edema is associated with posterior tibial tenosynovitis (PTTS). **Methods:** Sonographic images of the medial ankle soft tissues from 40 patients with PTTS and 37 patients with a normal posterior tibial tendon (PTT) were randomized and independently evaluated by two musculoskeletal radiologists for the presence or absence of subQ edema. Both radiologists were blinded to the images and status of the PTT and the patient's history. Statistical analyses included the Chi-square test and Cohen's Kappa statistics for inter-observer agreement. **Results:** A statistically significant association was seen for the presence of medial ankle subQ edema and PTTS among both radiologists' findings. Of the 40 patients with PTTS, 33 (82.5%) were found positive by the first radiologist for medial ankle subQ edema, while no subQ edema was found in 28 of the 37 (75.7%) patients with a normal PTT ($P < 0.001$). Similarly, the second radiologist found that 33 of the 40 (82.5%) with PTTS were positive for subQ edema, while no subQ edema was found in 24 of the 37 (64.9%) patients with a normal PTT ($P < 0.001$). There was also substantial inter-observer agreement between the 2 radiologists (κ -value = 0.79; 95% confidence intervals: 0.65, 0.93). **Conclusion:** A statistically significant association was present for the association of the sonographic finding of medial ankle subQ edema and the presence of PTTS. Further studies could evaluate if the sonographic finding of medial ankle subQ edema is an early predictor of PTT dysfunction.

Keywords: Ankle, hindfoot pes planovalgus, musculoskeletal ultrasound, posterior tibial tendon dysfunction, posterior tibial tenosynovitis, subcutaneous edema

INTRODUCTION

Posterior tibial tendon dysfunction (PTTD) is one of the most common associated conditions with adult acquired pes planus and most commonly occurs in middle-aged to elderly women.^[1-6] However, athletes may also be affected, especially those involved in high stress or repetitive activities.^[3,7-10] PTTD refers to a spectrum of abnormalities of the posterior tibial tendon (PTT) resulting in decreased tendon functionality. The one end of the spectrum includes posterior tibial tenosynovitis (PTTS) and on the other end, complete rupture of the PTT with a marked clinical deformity.^[3-5] If not diagnosed and treated early, it can result in significant pain, disability, and a hindfoot pes planovalgus deformity requiring invasive and complex surgical treatments.^[1-6,11-20] In the PTTD staging classification developed by Johnson and Strom in 1989, PTTS is considered stage 1.^[2,3,21-23] Furthermore, tenosynovial fluid, even with a normal-appearing PTT, has been shown to be

an early indication of stage 1 PTTD.^[24] Therefore, earlier detection of PTTS is critical, allowing the use of conservative treatments which have been shown to slow the progression of the disease.^[2-5,25-28]

The evaluation for PTTD includes both clinical and imaging findings. DeOrio *et al.*, in 2011, described a clinical finding that corresponds with PTTD referred to as "the posterior tibial edema sign."^[29] This finding of pitting subcutaneous (subQ) edema at the medial ankle, along the course of the PTT, was validated in a small subset of their study cohort, utilizing magnetic resonance imaging (MRI). However, the use of musculoskeletal (MSK) ultrasound (US) has significantly increased over the past decades, given its many advantages

Address for correspondence: Dr. Steven B. Soliman,
Department of Radiology, Henry Ford Hospital, 2799 West Grand Blvd.,
Detroit, MI 48202, USA.
E-mail: stevens@rad.hfh.edu

Received: 06-01-2021 Revised: 21-01-2021 Accepted: 09-02-2021 Available Online: 23-04-2021

Access this article online

Quick Response Code:



Website:
www.jmuonline.org

DOI:
10.4103/JMU.JMU_4_21

This is an open access journal, and articles are distributed under the terms of the Creative Commons Attribution-NonCommercial-ShareAlike 4.0 License, which allows others to remix, tweak, and build upon the work non-commercially, as long as appropriate credit is given and the new creations are licensed under the identical terms.

For reprints contact: WKHLRPMedknow_reprints@wolterskluwer.com

How to cite this article: Dammeyer KL, Klochko CL, Soliman SB. Sonographic finding of medial ankle subcutaneous edema and its association with posterior tibial tenosynovitis. J Med Ultrasound 2022;30:20-5.

and lower cost when compared to MRI.^[3,30,31] US has also been shown to be highly sensitive, accurate, and specific for PTTD, and furthermore, it has been reported that US is slightly more accurate than 3 Tesla MRI in the diagnosis of PTTD.^[2-4,21,32,33] Since PTTD is based on the tendon's functionality, the unique dynamic features of US allow the radiologist to determine a degree of function through imaging.^[3] Given these benefits and advantages, we found it imperative to evaluate this association utilizing US.

The purpose of this study is to evaluate the association of the sonographic finding of medial ankle subQ edema and PTTS to help determine if this US finding could be an early indicator of PTTD. This simple sonographic finding, if detected early, could allow prompt intervention to prevent further complications and healthcare costs related to the progression of PTTD.

MATERIALS AND METHODS

This study was performed in accordance with the ethical standards of our institutional research committee and with the 1964 Declaration of Helsinki and its later amendments or comparable ethical standards. Institutional review board approval was obtained for this retrospective study, and informed consent was waived (Henry Ford Health System IRB # 13862, May 3, 2020). Our study complied with the Health Insurance Portability and Accountability Act.

Selection of study cohorts

This retrospective study had a target population including all adult patients from July 2015 to March 2020 found by chart review and review of the radiology information system database to have had an ankle US with the reported diagnosis of either PTTS or a normal PTT. This resulted in 57 patients with PTTS and 48 patients with a normal PTT.

All the examinations were performed by trained dedicated MSK sonographers, all of whom possess the registered MSK sonographer designation through the American Registry for Diagnostic Medical Sonography (Rockville, MD). Each US was performed utilizing 9-18-MHz linear transducers (GE LOGIQ E9 unit; General Electric Company, Milwaukee, WI). The US examinations were interpreted by 1 of 9 fellowship-trained MSK radiologists, all of whom are highly skilled in MSK US performance and interpretation (clinical experience ranging from 3 to 33 years). These examinations were performed and interpreted in real-time, prior to any knowledge of this study.

Exclusion criteria by search of these US reports and chart review consisted of those patients with a prior PTT repair, a history of ankle or foot trauma or cellulitis within 3 months, or other causes of subQ edema including a history of lymphedema, generalized edema, anasarca, congestive heart failure, chronic venous insufficiency, hepatic disease, ascites, renal disease, or dialysis. Furthermore, those US ankle examinations that did not include the medial ankle, those not performed for evaluation of the PTT (e.g., tibial nerve),

or those performed only for the purposes of an US-guided injection were excluded.

The final study cohorts consisted of the remaining patients; one group of 40 patients with PTTS and one group of 37 patients with a normal PTT. Demographic information about age and gender, in addition to body mass index (BMI) and body weight, were recorded for these 77 patients. Using that sample size along with a two-sided alpha level of 0.05, the Chi-square test would allow us to achieve a statistical power of 99%.

For each of these 77 US examinations, a radiology resident placed the study in the original presentation state and it was de-identified so that all image markings and annotations were removed. A single, static, representative, short-axis US image of the medial ankle with the PTT, at the level of 1 cm proximal to the tip of the medial malleolus was then saved. These 77 images were then cropped [Figures 1 and 2] to include only the subQ tissues, without the PTT or tendon sheath, and were placed in an image viewer in a random order, using a random number generator.

Examination review

Those 77 US images were then evaluated independently by 2 fellowship-trained MSK radiologists (11 years and 3 years of clinical experience, respectively), who both have specific training and experience with MSK US. These 2 MSK radiologists separately reviewed the randomized 77 static images of the subQ tissues, blinded to the status and images of the PTT, patient cohort, and the patient's history, and assigned each image as positive or negative for the presence of subQ edema.

SubQ edema was considered positive when the subQ fat appeared thickened, echogenic, and demonstrated linear to curvilinear hypoechoic to anechoic areas interposed between the surrounding more echogenic fat, corresponding with fluid [Figure 1]. The positive subQ edema designation was reserved for those that would be considered severe subQ edema by Yabunaka, *et al.* and grade 2 (highest grade) by Suehiro, *et al.*^[34,35] Those that were equivocal for meeting these criteria and those having normal-appearing subQ fat were given a negative designation [Figure 2a].

Statistical analysis

The association between the presence or absence of medial ankle subQ edema and the presence or absence of PTTS by US was evaluated. Demographic comparisons of age and gender, in addition to BMI and body weight, were also performed between those with PTTS and those with a normal PTT. The comparisons were performed using Chi-square tests for categorical data and the two-sided sample t-tests for numerical data. The sensitivity and specificity were also calculated. In addition, the Cohen Kappa statistics were used to determine the degree of inter-observer agreement between the 2 MSK radiologists. All analyses were performed using SAS 9.4 (SAS Institute Inc., Cary, NC, USA). Statistical significance was defined as a $P < 0.05$.

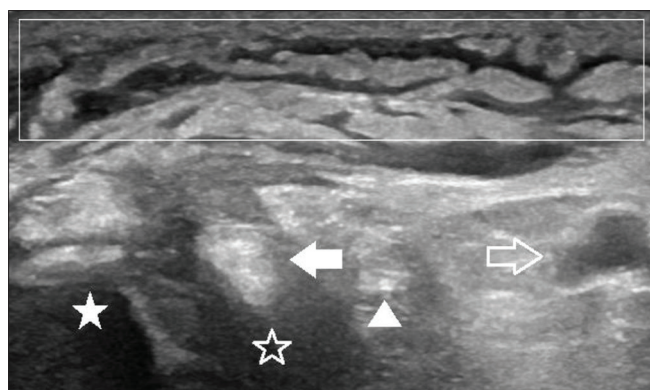


Figure 1: Sonographic findings of medial ankle subcutaneous edema and posterior tibial tenosynovitis in a 48-year-old woman with severe left medial ankle pain. Short-axis ultrasound image demonstrates increased echogenicity of the subcutaneous fat with interposed curvilinear hypoechoogenicity corresponding with fluid and consistent with severe subcutaneous edema (empty rectangle). The empty rectangle also depicts the area cropped for the radiologist image review. The posterior tibial tendon (solid arrow) is also seen adjacent to the medial malleolus (solid star). Posterior tibial tenosynovitis is manifest by complex hypoechoogenicity in the tendon sheath (empty star), circumferentially surrounding the tendon. The flexor digitorum longus tendon (triangle) and posterior tibial artery and paired veins are also present (empty arrow)

RESULTS

Study groups

Of the 40 patients with PTTS, 25 (62.5%) were women and 15 (37.5%) were men. The age range was 21–75 years with a mean age of 52.4. The mean BMI was 32.8 kg/m² and the mean body weight was 94.4 kg.

Of the 37 patients with a normal PTT, 28 (75.7%) were women and 9 (24.3%) were men. The age range was 18–70 years with a mean age of 46.5. The mean BMI was 33.3 kg/m² and the mean body weight was 93.9 kg.

Findings

The first MSK radiologist designated 42 of the total 77 images as positive for medial ankle subQ edema and 35 as negative for edema [Table 1]. A total of 33 of the 40 (82.5%) patients with PTTS were labeled as positive for subQ edema and 28 of the 37 (75.7%) patients with a normal PTT were labeled as negative for subQ edema (sensitivity 82.5%, specificity 75.7%). Of those 42 labeled as positive for subQ edema, 33 (78.6%) had PTTS. Of the 35 designated as negative for subQ edema, 28 (80%) had a normal PTT.

The second MSK radiologist labeled 46 of the total 77 images as positive for medial ankle subQ edema and 31 as negative for edema [Table 1]. A total of 33 of the 40 (82.5%) patients with PTTS were labeled as positive for subQ edema and 24 of the 37 (64.9%) patients with a normal PTT were labeled as negative for subQ edema (sensitivity 82.5%, specificity 64.9%). Of those 46 designated as positive for subQ edema, 33 (71.7%) had PTTS. Of the 31 labeled as negative for subQ edema, 24 (77.4%) had a normal PTT.

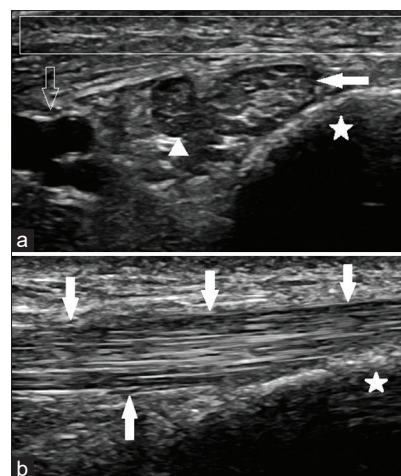


Figure 2: Normal sonographic appearance of the right medial ankle and posterior tibial tendon in a 34-year-old man. (a) Short-axis and (b) long-axis ultrasound images demonstrate the normal appearance of the subcutaneous fat with the absence of any edema (empty rectangle). The empty rectangle also represents the area cropped for the image review. The normal posterior tibial tendon (solid arrows) at the level of the medial malleolus (stars) is also shown with the normal homogenous, defined, hyperechoic, fibrillary pattern and no evidence of tenosynovitis. The flexor digitorum longus tendon (triangle) and posterior tibial vascular structures are also depicted (empty arrow)

Concerning inter-observer agreement, the 2 MSK radiologists demonstrated substantial agreement (κ -value = 0.79; 95% confidence intervals: 0.65, 0.93) with only 8 of the 77 image labels (4 from each group) being discordant.

Statistical significance

Statistical significance was seen when accounting for both MSK radiologists' findings [Table 1]. The first MSK radiologist's findings of positive medial ankle subQ edema in 33 of the 40 (82.5%) patients with PTTS and no subQ edema in 28 of the 37 (75.7%) patients with a normal PTT is statistically significant ($P < 0.001$).

Similarly, the second MSK radiologist's findings of positive medial ankle subQ edema in 33 of the 40 (82.5%) patients with PTTS and no subQ edema in 24 of the 37 (64.9%) patients with a normal PTT is also statistically significant ($P < 0.001$).

In regards to age, those with PTTS were slightly older than those with a normal PTT, albeit statistically insignificant ($P = 0.065$) [Table 2]. No statistical significance was identified in regards to gender, BMI, or body weight when comparing those with PTTS to those with a normal PTT [Table 2].

DISCUSSION

At a large institution performing a substantially high volume of MSK US, we found it essential to perform a study, specifically utilizing US, to determine the association between medial ankle subQ edema and PTTS in an effort to help detect PTTD at an earlier stage. Our findings demonstrate a statistically significant association for the sonographic finding of medial ankle subQ edema and the presence of PTTS.

Table 1: Associations between medial ankle subcutaneous edema and posterior tibial tenosynovitis for both reviewing musculoskeletal radiologists

	Tenosynovitis (n=40), n (%)	Normal tendon (n=37), n (%)	P
Radiologist 1			
Positive edema (n=42)	33 (82.5)	9 (24.3)	<0.001 (C)
No edema (n=35)	7 (17.5)	28 (75.7)	
Radiologist 2			
Positive edema (n=46)	33 (82.5)	13 (35.1)	<0.001 (C)
No edema (n=31)	7 (17.5)	24 (64.9)	

Categorical data is represented as frequency (percent of column). C=Chi-square test

Table 2: Patient demographics, body mass index, and body weight among the study cohorts and the significance between those with posterior tibial tenosynovitis and those with a normal posterior tibial tendon

Patient data	All patients (n=77)	PTTS (n=40)	Normal PTT (n=37)	P
Age, years (mean±SD)	50.5±13.9	52.4±12.6	46.5±14.8	0.065 (T)
Gender, n (%)				
Female	53 (68.8)	25 (62.5)	28 (75.7)	0.212 (C)
Male	24 (31.2)	15 (37.5)	9 (24.3)	
BMI, kg/m ² (mean±SD)	33±6.8	32.8±7.4	33.3±6.0	0.745 (T)
Body weight, kg (mean±SD)	94.1±22.5	94.4±18.9	93.9±25.5	0.923 (T)

Categorical data is represented as frequency (percent of column). Numerical data is represented as mean±SD. BMI: Body mass index, PTTS: Posterior tibial tenosynovitis, PTT: Posterior tibial tendon, SD: Standard deviation, C: Chi-square test and T: Two-sided sample *t*-test

The PTT is the primary stabilizer of the longitudinal arch of the foot.^[1,36-38] PTTD is one of the most common conditions associated with adult acquired pes planus, and if not diagnosed and treated early, can result in significant pain, disability, and a foot and ankle deformity with pes planus and hindfoot valgus (hindfoot pes planovalgus).^[1-3] In stage I, especially in the younger athletic population, PTTD may present with tenosynovitis.^[3,9,10,39] Although a small amount of compressible, anechoic, physiologic fluid can normally be seen in the PTT tendon sheath, this fluid should measure <1–2 mm in thickness and not be circumferential. In addition, there should not be any fluid at the distal 1–2 cm of the tendon which is devoid of a tendon sheath [Figure 2b].^[1,3,33] PTTS also presents as a hypoechoic rind surrounding the PTT within the sheath, resulting from complex fluid with associated echogenic debris or thickened synovium, with or without hyperemia [Figures 1 and 3].^[1,3,21,33]

Patients with PTTD often present with clinical findings such as medial foot pain, weakness, difficulty weight-bearing, or a flatfoot deformity. However, diabetic patients who are at a much higher risk for PTTD, if also neuropathic, often present late with PTT rupture and a hindfoot pes planovalgus deformity requiring complex surgical treatments.^[1,3,13,40] If these patients could be detected at an earlier stage, this could prevent further complications and unnecessary healthcare costs related to the more invasive and complex procedures required for treatments in the later stages of PTTD.

In 2011, DeOrio *et al.* described a clinical finding that corresponds with PTTD referred to as “the posterior tibial edema sign.”^[29] This sign refers to the presence of pitting edema that is more pronounced along the course of the

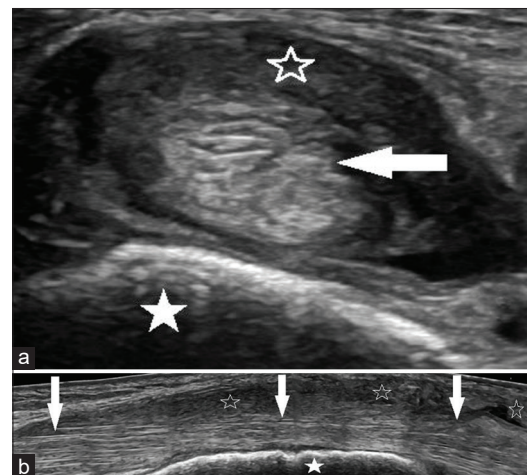


Figure 3: Sonographic images of posterior tibial tenosynovitis in a 62-year-old woman with severe left medial ankle pain. (a) Short-axis image and (b) long-axis panoramic image demonstrate significant posterior tibial tenosynovitis manifest by the complex hypoechoic rind and complex fluid within the tendon sheath (empty stars), circumferentially surrounding the posterior tibial tendon (arrows), adjacent to the medial malleolus (solid stars). The tendon (arrows) is also thickened and heterogeneously hypoechoic consistent with associated tendinosis

PTT, adjacent to the medial malleolus, when compared to the anterior tibia. Utilizing MRI for a small subset of their patient cohort, they found that this clinical finding was 86% sensitive and 100% specific for PTTD. Furthermore, in 2019, Gonzalez *et al.*, also using MRI, found that even with a normal-appearing PTT, in the absence of MRI-detectable intrasubstance tendon pathology, PTTS corresponded with stage 1 PTTD.^[24]

US or MRI plays a crucial role in the diagnosis and staging of PTTD.^[2-4,21,33] MSK US at our institution is most often used to evaluate the PTT. US has been shown to have a similar accuracy to MRI in diagnosing PTTD with a reported sensitivity of 100%, accuracy of 93%, and specificity of 88% in detecting PTT tears.^[2-4,21,32,33] In one study, high-resolution US has even been shown to be slightly more accurate than 3 Tesla MRI in the diagnosis of PTTD.^[29] Furthermore, the dynamic capabilities of US with compression and real-time maneuvers are crucial in diagnosing tenosynovitis and tendon subluxation which can be early signs of PTTD.^[3,21,41,42] Additional benefits of using US over MRI include the ability to perform real-time Doppler analysis, the ease of accessibility and comparing with the contralateral side, and the lower cost.^[31] Given these advantages and benefits, US allows the radiologist to determine a degree of function through imaging.^[3] Therefore, US has been recommended as the imaging modality of choice for PTTD.^[3,4,21,32]

The findings of our study suggest that when medial ankle subQ edema is seen by US, this should signal further interrogation of the PTT. This is especially the case in those having ankle US examinations for reasons other than evaluating the PTT, for example, in those performed for the evaluation of tarsal tunnel syndrome or tibial neuropathy or a dedicated Doppler vascular study. Furthermore, with the increasing use of point-of-care US, if subQ edema is clinically suspected at the medial ankle, US can be a simple method for imaging confirmation and given this study's findings, suggests further evaluation for the diagnosis of PTTD.

The limitations of this study should be acknowledged when interpreting the results. First, given the retrospective nature of the study, we had a higher proportion of female patients, although similarly in both groups and expected in the PTTD group, since PTTD is more common in women. A future prospective investigation with a controlled equal number of male and female participants could be performed. Additionally, a future prospective study comparing different areas of the ankle and lower leg for differing degrees of subQ and correlating with the degree of PTTD may prove beneficial. Finally, we did not have correlative MRI findings to confirm the sonographic presence or absence of PTTD. In our institution, given the benefits of US, the majority of patients with ankle pain are evaluated using US and typically do not have a comparison or follow-up MRI.

CONCLUSION

The sonographic finding of medial ankle subQ edema, not associated with other underlying causes, is significantly associated with the presence of PTTD and therefore stage 1 PTTD. Further studies could evaluate if this simple sonographic finding is an early indicator of PTTD which if detected early, could potentially help prevent further complications and health-care costs related to the progression of the disease.

Acknowledgments

We would like to thank Meredith Van Harn, MS, Henry Ford Hospital, for her help with the statistics used in this manuscript. We also thank Stephanie Stebens, MLIS, AHIP, Henry Ford Hospital, for her editorial assistance in preparation of this manuscript.

Financial support and sponsorship

Nil.

Conflicts of interest

There are no conflicts of interest.

REFERENCES

- Schweitzer ME, Karasick D. MR imaging of disorders of the posterior tibialis tendon. *AJR Am J Roentgenol* 2000;175:627-35.
- Bubra PS, Keighley G, Rateesh S, Carmody D. Posterior tibial tendon dysfunction: An overlooked cause of foot deformity. *J Family Med Prim Care* 2015;4:26-9.
- Soliman SB, Spicer PJ, van Holsbeeck MT. Sonographic and radiographic findings of posterior tibial tendon dysfunction: A practical step forward. *Skeletal Radiol* 2019;48:11-27.
- Premkumar A, Perry MB, Dwyer AJ, Gerber LH, Johnson D, Venzon D, *et al.* Sonography and MR imaging of posterior tibial tendinopathy. *AJR Am J Roentgenol* 2002;178:223-32.
- Zaw H, Calder JD. Operative management options for symptomatic flexible adult acquired flatfoot deformity: A review. *Knee Surg Sports Traumatol Arthrosc* 2010;18:135-42.
- Balen PF, Helms CA. Association of posterior tibial tendon injury with spring ligament injury, sinus tarsi abnormality, and plantar fasciitis on MR imaging. *AJR Am J Roentgenol* 2001;176:1137-43.
- Woods L, Leach RE. Posterior tibial tendon rupture in athletic people. *Am J Sports Med* 1991;19:495-8.
- Conti SF. Posterior tibial tendon problems in athletes. *Orthop Clin North Am* 1994;25:109-21.
- Alrashidi Y, Alsayed HN, Alrabai HM, Valderrabano V. Posterior tibial tendon lesions and insufficiency. In: Valderrabano V, Easley M, editors. *Foot and Ankle Sports Orthopaedics*. Switzerland: Springer; 2016. p. 219-29.
- Teitz CC, Garrett WE Jr, Miniaci A, Lee MH, Mann RA. Tendon problems in athletic individuals. *J Bone Joint Surg Am* 1997;79:138-52.
- Hogan JF. Posterior tibial tendon dysfunction and MRI. *J Foot Ankle Surg* 1993;32:467-72.
- Parsons S, Naim S, Richards PJ, McBride D. Correction and prevention of deformity in type II tibialis posterior dysfunction. *Clin Orthop Relat Res* 2010;468:1025-32.
- Francisco R, Chiodo CP, Wilson MG. Management of the rigid adult acquired flatfoot deformity. *Foot Ankle Clin* 2007;12:317-27, vii.
- Myerson MS, Corrigan J. Treatment of posterior tibial tendon dysfunction with flexor digitorum longus tendon transfer and calcaneal osteotomy. *Orthopedics* 1996;19:383-8.
- McAlister JE, DeMill SL, So E, Hyer CF. Surgical planning for flexor digitorum longus tendon transfers: An Anatomic Study. *J Foot Ankle Surg* 2017;56:47-9.
- Cao HH, Tang KL, Lu WZ, Xu JZ. Medial displacement calcaneal osteotomy with posterior tibial tendon reconstruction for the flexible flatfoot with symptomatic accessory navicular. *J Foot Ankle Surg* 2014;53:539-43.
- Graves SC, Stephenson K. The use of subtalar and triple arthrodeses in the treatment of posterior tibial tendon dysfunction. *Foot Ankle Clin* 1997;2:319-28.
- Knupp M, Stufkens SA, Hintermann B. Triple arthrodesis. *Foot Ankle Clin* 2011;16:61-7.
- Bennett GL, Graham CE, Mauldin DM. Triple arthrodesis in adults. *Foot Ankle* 1991;12:138-43.
- Kelly IP, Nunley JA. Treatment of stage 4 adult acquired flatfoot. *Foot*

- Ankle Clin 2001;6:167-78.
21. van Holsbeeck MT, Introcaso JH, editors. Musculoskeletal Ultrasound. 3rd ed. Philadelphia, PA: Jaypee Brothers Medical Publishers; 2016.
22. Johnson KA, Strom DE. Tibialis posterior tendon dysfunction. Clin Orthop Relat Res 1989;239:196-206.
23. Abousayed MM, Tartaglione JP, Rosenbaum AJ, Dipreta JA. Classifications in brief: Johnson and Strom classification of adult-acquired flatfoot deformity. Clin Orthop Relat Res 2016;474:588-93.
24. Gonzalez FM, Harmouche E, Robertson DD, Umpierrez M, Singer AD, Younan Y, *et al.* Tenosynovial fluid as an indication of early posterior tibial tendon dysfunction in patients with normal tendon appearance. Skeletal Radiol 2019;48:1377-83.
25. Blasimann A, Eichelberger P, Brühlhart Y, El-Masri I, Flückiger G, Frauchiger L, *et al.* Non-surgical treatment of pain associated with posterior tibial tendon dysfunction: study protocol for a randomised clinical trial. J Foot Ankle Res 2015;8:37.
26. Geideman WM, Johnson JE. Posterior tibial tendon dysfunction. J Orthop Sports Phys Ther 2000;30:68-77.
27. Parvizi J, Kim GK. Posterior tibial tendon dysfunction. In: Parvizi J, Kim GK, editors. High Yield Orthopaedics. Philadelphia, PA: Elsevier; 2010. p. 395-6.
28. Collins JM, Smithuis R, Rutten MJ. US-guided injection of the upper and lower extremity joints. Eur J Radiol 2012;81:2759-70.
29. DeOrio JK, Shapiro SA, McNeil RB, Stansel J. Validity of the posterior tibial edema sign in posterior tibial tendon dysfunction. Foot Ankle Int 2011;32:189-92.
30. van Holsbeeck M, Soliman S, Van Kerkhove F, Craig J. Advanced musculoskeletal ultrasound techniques: What are the applications? AJR Am J Roentgenol 2021;216:436-45.
31. Alves TI, Girish G, Kalume Brigido M, Jacobson JA. US of the knee: Scanning techniques, pitfalls, and pathologic conditions. Radiographics 2016;36:1759-75.
32. Arnoldner MA, Gruber M, Syré S, Kristen KH, Trnka HJ, Kainberger F, *et al.* Imaging of posterior tibial tendon dysfunction – Comparison of high-resolution ultrasound and 3T MRI. Eur J Radiol 2015;84:1777-81.
33. Donovan A, Rosenberg ZS, Bencardino JT, Velez ZR, Blonder DB, Ciavatta GA, *et al.* Plantar tendons of the foot: MR imaging and US. Radiographics 2013;33:2065-85.
34. Yabunaka K, Murayama R, Tanabe H, Takahashi T, Oe M, Oya M, *et al.* Ultrasonographic classification of subcutaneous edema caused by infusion via peripheral intravenous catheter. J Med Ultrasound 2016;24:60-5.
35. Suehiro K, Morikage N, Murakami M, Yamashita O, Ueda K, Samura M, *et al.* Subcutaneous tissue ultrasonography in legs with dependent edema and secondary lymphedema. Ann Vasc Dis 2014;7:21-7.
36. Moore KL, Dalley AF, Agur AM. Clinically Oriented Anatomy. 8th ed. Baltimore, MD: Lippincott Williams & Wilkins; 2017.
37. Kelikian AS, Sarrafian SK. Sarrafian's Anatomy of the Foot and Ankle: Descriptive, Topographic, Functional. 3rd ed.. Philadelphia, PA: Lippincott Williams & Wilkins; 2011.
38. Standring S. Gray's Anatomy: The Anatomic Basis of Clinical Practice. 41st ed. Philadelphia, PA: Elsevier; 2016.
39. Donovan A, Rosenberg ZS. Extraarticular lateral hindfoot impingement with posterior tibial tendon tear: MRI correlation. AJR Am J Roentgenol 2009;193:672-8.
40. Ahmad J, Pedowitz D. Management of the rigid arthritic flatfoot in adults: Triple arthrodesis. Foot Ankle Clin 2012;17:309-22.
41. Lhoste-Trouilloud A. The tibialis posterior tendon. J Ultrasound 2012;15:2-6.
42. Jacobson JA. Fundamentals of Musculoskeletal Ultrasound. 3rd ed. Philadelphia, PA: Elsevier; 2018.